



PATIENT

Hank Tucker

SPECIES

Canine

BREED

Rottweiler

SEX

Male

AGE

15 weeks

WEIGHT

39lbs

INTERPRETED BY

Maggie Machen
Lamy, DVM
DACVIM (Cardiology)

IMAGING PERFORMED BY

Pamela Harrigan,
RDCS

HOSPITAL NAME

Mass Veterinary Services

REFERRING VET

Dr. Masloski

INVOICE

28853

DATE

2/8/23

PRESENTING CLINICAL SIGNS

History: Hank is referred to evaluate a heart murmur. He frequently pants and does not seem to have the energy that would be expected from a puppy. He sleeps for approximately 4 hours after going for a walk. He continues to have a good appetite. On exam: NSR, grade IV/VI murmur noted best at base, PSS, lung fields clear, mm pink, moist, CRT < 2. BP: 120mmHg x 4. *Sedated with propofol for study.

ECHOCARDIOGRAM FINDINGS

2D, m-mode, color flow and Doppler imaging is available.

Left ventricle: The LV chamber is normal with severe LV hypertrophy. The endocardium appears hyperechoic. Moderate papillary muscle hypertrophy.

Left atrium: The left atrium is normal.

Mitral valve: The anterior mitral valve leaflet is abnormal, with thickening and elongation of the anterior leaflet. SAM is visualized. Trace eccentric mitral regurgitation.

Aortic valve/aorta: The aortic valve appears trileaflet and mildly thickened. Moderate aortic insufficiency. Prominent coronary arteries. Significant narrowing of the LVOT appreciated.

Right ventricle: Normal right ventricular diameter and morphology indicating no overt evidence of pulmonary arterial hypertension.

Right atrium: Normal RA dimension.

Tricuspid valve: The tricuspid valve appears normal with trace TR. Normal velocity.

Pulmonic valve/pulmonary artery: The pulmonic valve is normal in morphology and mobility. No pulmonic insufficiency. Normal RVOT velocity; laminar flow.

Pericardium/other: No pericardial or pleural effusion noted. No congenital shunts appreciated. No obvious cardiac masses.

Heart rhythm: ECG reveals a sinus rhythm with an average HR of 150bpm.

2-Dimensional Measurements

Ao diam (cm)	2.0
LA diam (cm)	2.4
LA:Ao (Swe)	1.2
IVS thickness (cm)	1.4
LVID diastole (cm)	2.1
PW thickness (cm)	14
LVID systole (cm)	1.0
FS (%)	52

Doppler Measurements

PV Vmax (m/s)	1.2
AoV Vmax (m/s)	5.4
MR Vmax (m/s)	NM
TR Vmax (m/s)	2.7
TR PG (mmHg)	30

INTERPRETATION OF THE FINDINGS

The cause of the murmur is severe subaortic stenosis (SAS) causing elevated blood flow velocity through the LVOT. The valve is also mildly thickened; however, the primary issue appears subvalvular. A significant aortic leak is noted, which should be monitored going forward. Further contributing to the outflow obstruction is a dysplastic mitral valve, causing a dynamic obstruction as well. The LV walls are severely increased indicating pressure overload of the left heart. The outflow velocity places the disease in the severe category with marked cardiac remodeling given the young age of the patient. No additional issues are identified.

No surgical intervention is widely available at this time; however, advanced options could be discussed at an academic institution. Medical management through heart rate control is



PATIENT
Hank Tucker

recommended as below, in hopes of decreasing the obstruction long term. Typically, this medication is not initiated until 6 months; however, given the severity of what is seen here the benefit likely outweighs the risk.

SPECIES
Canine

Prognosis is guarded yet highly variable, with many dogs in the severe category succumbing to malignant arrhythmias by mid-life and others maintaining asymptomatic status long term. Serial echocardiography is recommended lifelong to assess for progression and risk for complication.

BREED
Rottweiler

RECOMMENDATIONS

SEX
Male

- Once 4 mo of age, institute atenolol to effect: 0.5-1.5mg/kg SID-BID (up-titrate to desired effect). Goal is to suppress heart rate <130bpm even with stress/activity.
- Consider referral as discussed to explore surgical options if desired.
- Omega fatty acid supplementation and mild salt restriction may be of some long term anti-arrhythmic benefit.

AGE
15 weeks

- Once Atenolol is initiated, anesthetic risk is mild if needed. Avoid heart rate stimulating drugs such as atropine or glycopyrrolate unless clinically indicated. Avoid ketamine and acepromazine due to systemic vascular effects. Mild IV fluid restriction is advised. Recommend prophylactic antibiotics for any orthopedic or dental procedure in the future given predisposition to endocarditis.

WEIGHT
39lbs

- Monitor for development of labored breathing, exercise intolerance or collapse episodes, as AS patients are more predisposed to development of arrhythmias than to CHF.
- Moderate lifelong exercise restriction is advised.

INTERPRETED BY

Maggie Machen
Lamy, DVM
DACVIM (Cardiology)

PLAN

- Recommend conservative monitoring with a recheck echocardiogram in 6-12 months, sooner if any development of clinical signs.

IMAGING PERFORMED BY

Pamela Harrigan,
RDCS

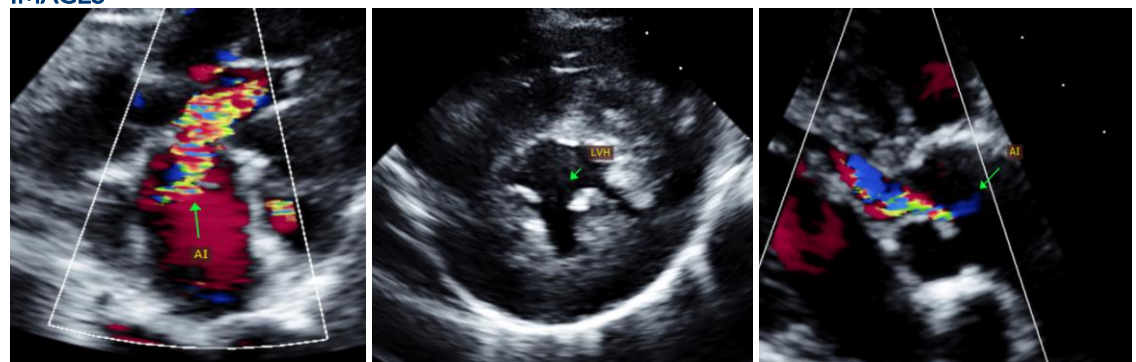
HOSPITAL NAME

Mass Veterinary Services

REFERRING VET

Dr. Masloski

IMAGES

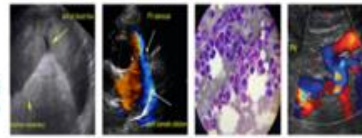


INVOICE

28853

DATE

2/8/23



PATIENT

Hank Tucker

SPECIES

Canine

BREED

Rottweiler

SEX

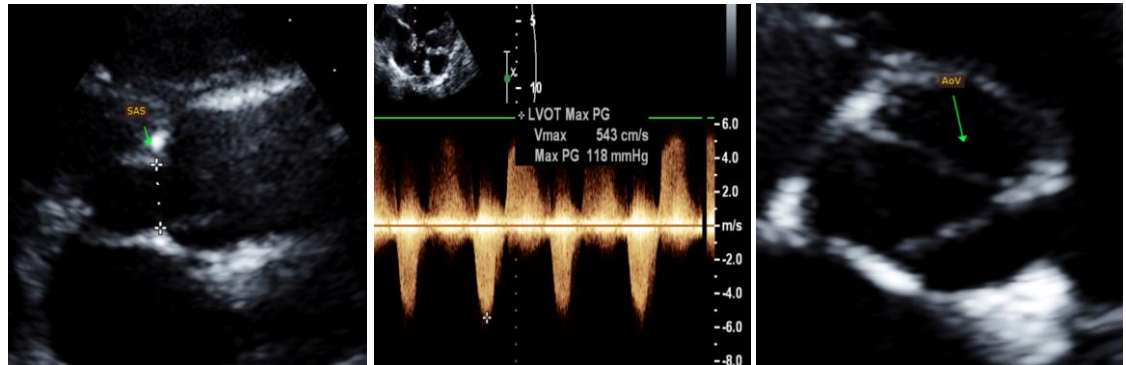
Male

AGE

15 weeks

WEIGHT

39lbs



The information and recommendations provided are based on the images presented by the referring veterinarian. No evaluation can be communicated regarding pathology that was not visible in the image/video clips provided.

Thank you for this referral. This report was generated using transcription software, and minor dictation errors may be present. If the clinical or image interpretation does not parallel your findings or if I can be of any further assistance, please contact me.

Maggie Machen Lamy, DVM
Diplomate of the American College of Veterinary Internal Medicine (Cardiology)
info@sonopath.com

INTERPRETED BY

Maggie Machen
Lamy, DVM
DACVIM (Cardiology)

Echocardiogram performed by:

Pamela Harrigan, RDCS
Pet Animal Ultrasound Service (4paus.com)

IMAGING PERFORMED BY

Pamela Harrigan,
RDCS

HOSPITAL NAME

Mass Veterinary
Services

REFERRING VET

Dr. Masloski

INVOICE

28853

DATE

2/8/23